

Unusual presentation of a perforated appendicitis in a four-year-old girl - a case report from Yazd, Iran

Mohammadhosain Afrand¹, Vajiheh Modaresi²

¹ Medical Scientific Association, Student of Public health, Islamic Azad University, Yazd branch, Yazd, Iran

² Assistant professor of Pediatric Gastroenterology, Pediatric Department, Islamic Azad University, Yazd branch, Yazd, Iran

Corresponding Author:

Mohammadhosain Afrand, Medical Scientific Association, Islamic Azad University, Yazd branch, Yazd, Iran.
Postal code: 8917145438, Tel: +98.3517237280, Fax: +98.3515231421, Email: hosain.afrand@yahoo.com

Abstract

Difficulties in the early diagnosis of appendicitis, particularly in children, often lead to complications, such as perforation of the appendix, within 36 hours of the onset of symptoms. A four-year-old girl presented to the Emergency Department at Shohadaye Kargar Hospital in Yazd (a city in central Iran) in February 2013 with a history of chronic abdominal pain that began 20 days before admission. Her physical examination revealed a low-grade fever, conjunctivitis, dysuria with malodorous urine, and a mass in right, lower quadrant without localized tenderness in that area. Intestinal intussusception was suggested as the most likely diagnosis, and a laparotomy was performed. The appendix was perforated and an appendicular abscess had caused intestinal obstruction. The rarity of this case, with its unusual presentation and findings, which included unexplained chronic pain, necessitated an immediate operation that revealed the acute presentation of a mechanical obstruction of the intestine. Appendicitis must be kept in the differential diagnosis of any child who presents with chronic abdominal pain. In conclusion, chronic abdominal pain in children is not always of functional origin, and discerning the correct diagnosis can be very challenging. Therefore, clinicians should think broadly since multi-disciplinary input may be inevitable.

Keywords: perforated appendicitis; appendicular abscess; abdominal pain; children

Additional Information for citing this article:

Title of Journal: Electronic physician; Abbreviated title of journal: Electron. Physician
doi: 10.14661/2014.788-793

Editorial information:

Type of article: Case report

Received: November.28.2013

Revised: 1st Revision: December.16.2013; 2nd Revision: January.06.2014; 3rd Revision: February.06.2014

Accepted: February.09.2014

Published: May.10.2014

© 2014 The Authors. This is an open access article under the terms of the Creative Commons Attribution-NonCommercial-NoDerivs License, which permits use and distribution in any medium, provided the original work is properly cited, the use is non-commercial and no modifications or adaptations are made.

1. Introduction

Appendicitis is a relatively rare cause of chronic or recurrent abdominal pain in children. Appendicitis can usually be diagnosed based on a thorough history and physical examination (abdominal pain, vomiting, tenderness and guarding in the right, lower quadrant), and laboratory evaluation with a urine analysis and white blood cell count (WBC) can be helpful. X-rays of the chest and abdomen can be helpful for differential diagnosis in a few cases, but they cannot be used to diagnose appendicitis conclusively (1). The difficulties associated with obtaining a careful history of appendicitis in infants and young children makes its accurate diagnosis challenging. Difficulties in the early diagnosis of appendicitis, especially in children, often lead to complications, such as perforation of the appendix within 36 hours of the onset of symptoms. After perforation, either diffuse peritonitis ensues or a localized abscess forms. In younger children, their underdeveloped omenta often cannot contain the purulent material (2). Accordingly, diffuse peritonitis occurs more frequently after perforation of the appendix in children who are less than five years old (3). Complications might occur as early as six hours after the onset of symptoms in such children. Thus, most children younger than 5 who present with abdominal pain already have a perforated appendicitis at the time of operation (4, 5). However, the complications commonly associated with appendicitis, such as the formation of an abscess and perforation of the appendix, are decreasing due to the use of advanced diagnostic tools, such as

computed tomography scanning (CT scan) of the abdominal area. The poor cooperation of pediatric patients may preclude the performance of an optimal physical examination. In addition, the characteristic laboratory findings often are not present. In young infants, leukopenia is as common as leukocytosis (6). As a result, misdiagnosis is common, and the occurrence of complicated appendicitis can be as high as 40 to 70% among pediatric patients who present with abdominal pain (5). Perforation, with resultant peritonitis, abscess, and portal pylephlebitis are the main complications of untreated appendicitis. Perforation rates as high as 90% have been reported in children younger than two, but these complications are certain to decrease as more useful diagnostic modalities, such as the abdominal CT scan, become more prevalent. Patients in the age range of 10 to 30 have the lowest perforation rate, i.e., 10 to 20% (7, 8). Appendicular abscess is a very rare complication of acute appendicitis, and it most frequently presents as an abdominal mass. Since it is not easy to diagnose this rare presentation preoperatively, most reported cases have recorded the existence of significant complications (9).

2. Case Presentation

2.1. Clinical presentation

A four-year-old girl was referred to the Emergency Department at Shohadaye Kargar Hospital in Yazd (a city in central Iran) in February 2013 with a history of abdominal pain that began 20 days before admission. She was suffering from fever, anorexia, constipation, nausea, vomiting, and dysuria with malodorous urine, all which began about 20 days before admission and led to her parents' seeking medical attention for her.

Table 1. Patient's blood test results compared to normal values

Lab test	Patient's value	Normal value for patient's age
WBC	$18.6 \times 10^3/\mu\text{L}$	$4.1-10.9 \times 10^3/\mu\text{L}$
RBC	4.01 mil/UL	3.6-6.1 mil/UL
POLYS	76.9%	35-80%
LYMP	17.4%	20-50%
Hgb	9.9 g/dL	10.5-14 g/dL
MCV	79.6 fL	78-101 fL (Female)
Platelet	$434 \times 10^3/\mu\text{L}$	$140-450 \times 10^3/\mu\text{L}$

WBC: white blood cells; RBC: red blood cells; POLYS: polymorphonuclear cells; LYMP: lymphocytes; Hgb: hemoglobin; MCV: mean corpuscular volume

Table 2. Patient's biochemical study results compared to normal values

Lab Tests	Patient	Normal range
AST	23 IU/L	12-38 IU/L
ALT	12 IU/L	7-41 IU/L
ALKP	328IU/L	180-1200 IU/L
AMS	20 IU/L	20-96 IU/L
BUN	14 mg/dL	7-20 mg/dL
Cr	0.5 ng/mL	0.5-0.9 ng/mL
Na	137 mEq/L	136-146 mEq/L
K	4.4 mEq/L	3.5-5.0 mEq/L
ESR	60	
CRP	1 mg/L	0.2-3.0 mg/L
BS	66 mg/dL	60-100 mg/dL

AST: aspartate aminotransferase; ALT: alanine aminotransferase; ALKP: alkaline phosphatase; AMS: amylase; BUN: blood urea nitrogen; Na: sodium; K: potassium; ESR: erythrocyte sedimentation rate; CRP: C - reactive protein; BS: blood sugar

2.2. Past history

Before arriving at the Emergency Department, she had been diagnosed as having a urinary tract infection (UTI) and viral gastroenteritis, and some medications had been prescribed for her, i.e., the administration of 75 mg of trimethoprim/sulfamethoxazole for seven days. Her condition did not improve during this time, so she was referred to the Emergency Department because of deteriorating clinical condition, and she was admitted to the surgery floor.

2.3. Physical examination

Physical examination revealed the following:

- General appearance: conjunctivitis, uncomfortable, preferred to lie down, normal gait, alert, and oriented child demonstrating behavioral signs of pain, including grimacing, moaning, and guarding of the abdomen
- Height, 105cm; weight, 17 kg
- Oral temperature: 38 °C
- Pulse: 82 beats/min
- Respiratory status: Bilateral breath sounds were equal and clear; respiratory rate was 17 breaths/min
- Skin was warm with no diaphoresis; nail beds and general skin color were pale
- Blood pressure: 100/70 mm Hg
- The patient described diffuse abdominal tenderness that was not localized to the right lower quadrant (RLQ), and there was no radiation or rebound tenderness when the physician palpated her abdomen. A mass was palpated in RLQ during the abdominal examination.
- Rovsing's sign and Psoas and obturator signs were negative.

2.4. Laboratory findings

The analysis of her blood and other biochemical analyses revealed an elevated white blood cell (WBC) count of $18.6/\mu\text{L}$ (normal values range from 4.1×10^3 to $10.9 \times 10^3/\mu\text{L}$), and 76.9% of the cells were polymorphonuclear cells (POLYS) (normal values range from 35 to 80%); an erythrocyte sedimentation rate (ESR) of 60 (normal values are < 20 for her age); hemoglobin (Hgb) was 9.9 g/dL (normal values range from 10.5 to 14 g/dL); and C-reactive protein (CRP) was positive. The rest of the routine blood and biochemical tests were unremarkable (Tables 1 and 2).

2.5. Imaging

Plain X-rays and abdominal ultrasound (US) were done. The findings from the abdominal radiographs included minimal gas in the right abdomen and the ascending colon. Ultrasound showed alternating rings and included the target and pseudokidney signs that are the hallmarks of ultrasonography in diagnosing intussusception (Figure 1). After consultation with the assistant attending surgeon, intestinal intussusception was suggested based on the radiographic evidence, and a barium enema was administered, but reduction was unsuccessful, indicating that there was a mechanical obstruction.

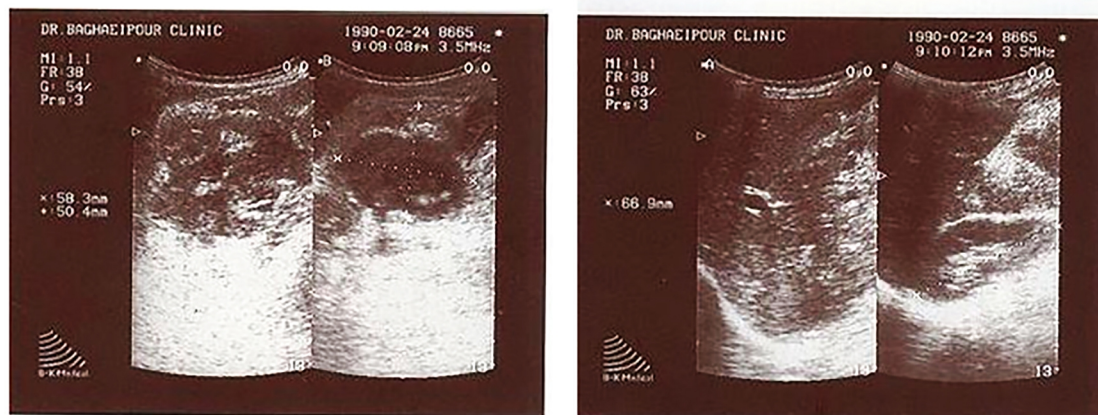


Figure 1. Abdominal sonography shows the classic target sign of an intussusceptum inside an intussuscipiens

2.5. Surgery procedure

Since the barium enema showed a mechanical obstruction, the parents were asked to provide their written consent for the surgical procedure. After the written consent was provided, general anesthesia was used to sedate the patient and then a laparotomy was performed via lower midline incision considering intussusception. The patient's appendix was perforated and an appendicular abscess had resulted in an intestinal obstruction. After a pre-operative preparation, a median laparotomy was performed. The exploration showed a large mass in the right, lower quadrant with 200 cm³ of pus (Figure 2), and there also were false membranes. Upon gross inspection, the perforated appendix was not seen in surgery region. Peritoneal toilet was subsequently performed and the specimen was sent

for histopathology. Surgical pathology confirmed acute appendicitis with suppurative necrosis of the serous membrane.

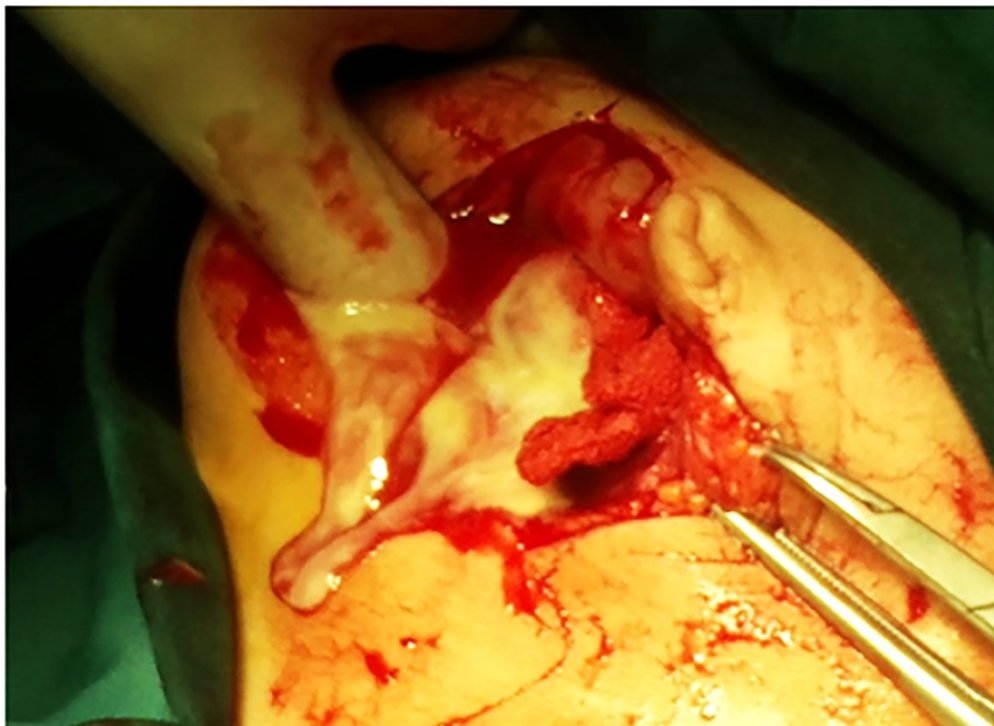


Figure 2. Appendicular abscess

2.6. Patient follow-up

The patient made an uneventful, post-operative recovery and was discharged on the second post-operative day. At the follow-up examinations at 10 days and one month after surgery she was doing well.

2.7. Ethical consideration

Informed consent was obtained directly and in writing from the patient's parents for publication of this manuscript and any accompanying images. Consent for the recommended clinical course of action and for research participation was freely given based on full prior knowledge of potential benefits and risks. This personal 'story' does not belong to the caregiver. It is the individual subject who possesses the original 'copyright.' This premise is reflected throughout our medical care system by carefully established privacy controls that protect against dissemination of patients' information to third parties without the consent of the affected individuals (10). The subject of a case report must be aware of both the premise and the undertaking whenever possible and feasible.

A corollary to the 'copyright' was obtained to preserve confidentiality. Wherever possible, the case report can be reviewed by the patient's parents to permit editing or removal of any confidential or compromising material, thus overtly respecting the 'copyright.' The caregiver and author were constantly aware of the need for informed consent and the protection of confidentiality, and this awareness provided an additional level of protection. The Medical Ethics Committee at Shohadaye Kargar Hospital approved the study protocol.

3. Discussion

Perforation, with resultant peritonitis, abscess, and portal pylephlebitis, are the main complications of untreated appendicitis. Overall, the perforation rate in most cases of appendicitis is between 10 and 30%, but the rate of perforation varies significantly with age. Perforation is most common at the extreme ends of age. Perforation rates as high as 90% have been reported in children younger than two years (11), and patients older than 70 have perforation rates between 50% and 70% (7, 8). Patients between the ages of 10 and 30 have the lowest perforation rate, generally between 10% and 20%. The risk of perforation seems to increase as the duration of illness increases,

particularly after 24 hours (12). Appendicitis presents as an incarcerated hernia, intermittent small bowel obstruction, subphrenic abscess, and diverticulitis.

In this case report, we also presented a rare case of appendicitis that presented with the typical presentation of some partial mechanical intestinal obstruction. In such as case, delay in diagnosis and treatment during initial evaluations result in critical complications in the child. The admission of such cases has a high probability of saving the patient's life. On the first day of hospitalization, because of possibility of intestinal intussusception, which was evident from the abdominal ultrasound (Figure 1), a barium enema was administered in an attempt to reduce the possible intussusception, but it was not successful. Laparotomy was considered for the patient who had a perforated appendicitis and an abscess that occluded the intestine. Thus, appendicitis must always be considered as the differential diagnosis of any child who presents with abdominal pain. When the abscess begins to leak into the abdominal cavity, the child will show signs of severe toxicity, oliguria, mottling of the skin, evidence of gram negative septicemia, and a decrease in platelet count. Radiographs may detect signs of paralytic ileus or even partial obstruction of the small bowel. Such patients are most at risk for complicating results (13). Comparing our case to other unusual presentations of appendicitis in children, perforation occurred within about 36 hours after the onset of symptoms. Shorter time periods for perforation to occur, sometimes just six hours, have been observed in children younger than five. Thus, most children younger than five have perforated appendices by the time the surgery is performed (4, 5).

4. Conclusions

The most impressive thing in this case was the presence of chronic abdominal pain caused by the child's perforated appendix and the formation of an abscess that obstructed the intestine after ultrasound images confirmed the diagnosis of intussusceptions. In this unusual presentation, there was a high risk of an incorrect diagnosis, because the typical signs of acute appendicitis, including tenderness at McBurney's point and peritonitis, were absent. The delayed diagnosis eventually led to the formation of an abscess, which could have been life threatening. Consequently, on reflection, our case presentation highlights the fact that abdominal pain in children can be misleading because it does not always have a functional origin, so clinicians should think broadly because multi-disciplinary input may be inevitable.

Acknowledgments:

The authors thank the patient's parents for their valuable contributions to this study. We also thank Ms. Hakimian and Mr. Sarebanhassanabadi for working closely with the project's coordinators and helping in the preparation of the manuscript. The authors also acknowledge the support and contributions to this study provided by the Ali-Ebne Abitaleb Faculty of Medicine at the Yazd Branch of Islamic Azad University in Yazd, Iran.

Conflict of Interest:

There is no conflict of interest to be declared.

Authors' contributions:

Both authors contributed to this project and article equally. All authors read and approved the final manuscript.

References:

1. Klein MD, Rabbani AB, Rood KD, Durham T, Rosenberg NM, Bahr MJ, et al. Three quantitative approaches to the diagnosis of abdominal pain in children: practical applications of decision theory. *J Pediatr Surg.* 2001; 36(9):1375-80. PubMed PMID: 11528609. DOI: <http://dx.doi.org/10.1053/jpsu.2001.26374>
2. Rasmussen OO, Hoffmann J. Assessment of the reliability of the symptoms and signs of acute appendicitis. *Journal of the Royal College of Surgeons of Edinburgh.* 1991 Dec;36(6):372-7. PubMed PMID: 1774704
3. Gilbert SR, Emmens RW, Putnam TC. Appendicitis in children. *Surgery, gynecology & obstetrics.* 1985 Sep;161(3):261-5. PubMed PMID: 4035541. Epub 1985/09/01.
4. Cappendijk VC, Hazebroek FW. The impact of diagnostic delay on the course of acute appendicitis. *Arch Dis Child.* 2000; 83(1):64-6. PubMed PMID: 10869003. Pubmed Central PMCID: PMC1718392. DOI: <http://dx.doi.org/10.1136/adc.83.1.64>
5. Nance ML, Adamson WT, Hedrick HL. Appendicitis in the young child: a continuing diagnostic challenge. *Pediatr Emerg Care.* 2000; 16(3):160-2. PubMed PMID: 10888451. Epub 2000/07/11. eng. DOI: <http://dx.doi.org/10.1097/00006565-200006000-00005>

6. Paajanen H, Mansikka A, Laato M, Kettunen J, Kostiainen S. Are serum inflammatory markers age dependent in acute appendicitis? *J Am Coll Surg.* 1997; 184(3):303-8. PubMed PMID: 9060929. Epub 1997/03/01. eng.
7. Franz MG, Norman J, Fabri PJ. Increased morbidity of appendicitis with advancing age. *Am Surg.* 1995; 61(1):40-4. PubMed PMID: 7832380. Epub 1995/01/01. eng.
8. Flum DR, Morris A, Koepsell T, Dellinger EP. Has misdiagnosis of appendicitis decreased over time? A population-based analysis. *JAMA.* 2001 10; 286(14):1748-53. PubMed PMID: 11594900. Epub 2001/10/12. eng. Available from: <http://jama.jamanetwork.com/data/Journals/JAMA/4803/JOC10703.pdf>
9. Dominguez JA, Planchar RM, Rocabert JI, Ortiz PL, Gil AC. [Medical and/or surgical treatment of appendicular mass and appendicular abscess in children]. *Cir Pediatr.* 2008; 21(1):43-5. PubMed PMID: 18444390.
10. Shevell MI. The ethics of case reports. *Paediatrics & child health.* 2004 Feb;9(2):83-4. PubMed PMID: 19654984. Available from: <http://www.ncbi.nlm.nih.gov/pmc/articles/PMC2720465/pdf/pch09083.pdf>
11. Rothrock SG, Pagane J. Acute appendicitis in children: emergency department diagnosis and management. *Ann Emerg Med.* 2000; 36(1):39-51. PubMed PMID: 10874234. Epub 2000/06/30. eng. DOI: <http://dx.doi.org/10.1067/mem.2000.105658>
12. Temple CL, Huchcroft SA, Temple WJ. The natural history of appendicitis in adults. A prospective study. *Ann Surg.* 1995; 221(3):278-81. PubMed PMID: 7717781, DOI: <http://dx.doi.org/10.1097/00000658-199503000-00010>
13. Becker T, Kharbanda A, Bachur R. Atypical clinical features of pediatric appendicitis. *Academic emergency medicine : official journal of the Society for Academic Emergency Medicine.* 2007 Feb;14(2):124-9. PubMed PMID: 17192449. Epub 2006/12/29. eng.